



PATIENT

Aleister Reyor-Kelly

SPECIES

Feline

BREED

DSH

SEX

Male Neutered

AGE

14 years

WEIGHT

13.56lbs

INTERPRETED BY

Maggie Machen
Lamy, DVM
DACVIM (Cardiology)

IMAGING PERFORMED BY

Pamela Harrigan,
RDCS

HOSPITAL NAME

Mass Veterinary Services

REFERRING VET

Dr. Masloski

INVOICE

26820

DATE

10/11/22

PRESENTING CLINICAL SIGNS

History: History hyperthyroidism well controlled on Methimazole. Heart murmur noted in July. Has been on mirtazapine on and off for appetite. Also transitioning to Z/D diet. On exam: NSR, grade II/VI parasternal murmur, PSS, lung fields clear, compressible thorax. BP: 140mmHg x 5. Medications: 1) Prednisolone 5mg ---not taking 2) Mirtazapine 15mg 1/4 tab every 3 days 3) Methimazole/tapazole 5mg 1/2 tab am with 1/4 tab pm *No sedation for study.

ECHOCARDIOGRAM FINDINGS

2D, m-mode, color flow and Doppler imaging is available.

Left ventricle: The LV diameter is normal with adequate myocardial function. The LV wall dimensions are borderline. There is mild fibrosis of the endocardium. The endocardium appears mildly remodeled. The papillary muscles appear hyperechoic and normal in dimension.

Left atrium: The left atrium is normal. No obvious smoke or thrombi seen.

Mitral valve: The mitral valve is normal in structure and mobility. No obvious systolic anterior motion is seen. No MR.

Aortic valve/aorta: The aortic valve is normal in morphology and mobility. Normal aortic outflow velocity; laminar flow. Trace aortic insufficiency.

Right ventricle: Normal right ventricular diameter and morphology indicating no overt evidence of pulmonary arterial hypertension.

Right atrium: The right atrium is normal in dimension.

Tricuspid valve: The tricuspid valve appears normal with trace tricuspid regurgitation.

Pulmonic valve/pulmonary artery: The pulmonic valve is normal in morphology and mobility. No pulmonic insufficiency. Normal RVOT velocity; laminar flow.

Pericardium/other: No pericardial or pleural effusion noted. No obvious cardiac masses.

Heart rhythm: ECG reveals a sinus rhythm with an average HR of 160bpm.

2-Dimensional Measurements

Ao diam (cm)	1.1
LA diam (cm)	1.2
LA:Ao (Swe)	1.1
IVS thickness (cm)	0.52
LVID diastole (cm)	1.58
PW thickness (cm)	0.56
LVID systole (cm)	0.73
FS (%)	56

Doppler Measurements

PV Vmax (m/s)	0.85
AoV Vmax (m/s)	1.4
MR Vmax (m/s)	NA
TR Vmax (m/s)	NA
TR PG (mmHg)	NA

INTERPRETATION OF THE FINDINGS

Overtly normal cardiac structure and function are identified. The LV wall thickness is borderline, which may be a normal variant or may reflect early hypertrophic changes. Follow up is advised. Mild remodeling fibrosis of the left ventricular wall is noted, which is likely a normal variant. A small aortic insufficiency is noted; however, the reported blood pressure is normal. No significant valve leaks are identified and flow through the great vessels is normal in velocity. No definitive cause is identified for the murmur in this study, making it likely physiologic in origin.

Prognosis is open.



PATIENT

Aleister Reyor-Kelly

SPECIES

Feline

BREED

DSH

SEX

Male Neutered

AGE

14 years

WEIGHT

13.56lbs

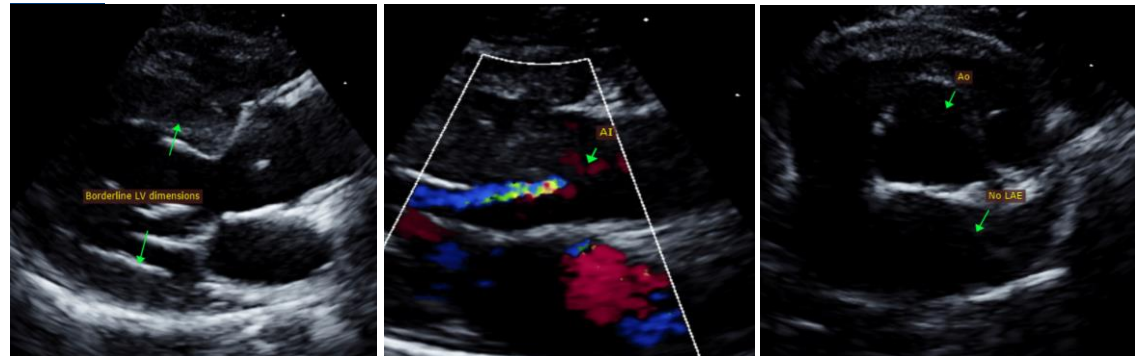
RECOMMENDATIONS

- Given these findings, no medications are indicated.
- No cardiac contraindication for general anesthesia. Should fluid or steroid therapy be indicated in the future, any cat should be monitored for intolerance (changes in RR/RE).
- Monitor at home for signs of cardiac compromise, including respiratory changes and/or signs of a blood clot event (paralysis, neurologic changes).

PLAN

- Recommend recheck echocardiogram in 6-12 months to assess for any progressive issues or development of disease the pre-existing murmur may mask.

IMAGES



INTERPRETED BY

Maggie Machen Lamy, DVM
DACVIM (Cardiology)

The information and recommendations provided are based on the images presented by the referring veterinarian. No evaluation can be communicated regarding pathology that was not visible in the image/video clips provided.

Thank you for this referral. This report was generated using transcription software, and minor dictation errors may be present. If the clinical or image interpretation does not parallel your findings or if I can be of any further assistance, please contact me.

IMAGING PERFORMED BY

Pamela Harrigan, RDCS

Maggie Machen Lamy, DVM
Diplomate of the American College of Veterinary Internal Medicine (Cardiology)
info@sonopath.com

HOSPITAL NAME

Mass Veterinary Services

Echocardiogram performed by:

Pamela Harrigan, RDCS
Pet Animal Ultrasound Service (4paus.com)

REFERRING VET

Dr. Masloski

INVOICE

26820

DATE

10/11/22